

## Anticoagulant Management of Mechanical Heart Valve Patients during Perioperative Surgery: A Case Report

Trisulo Wasyanto<sup>1)</sup>, Yoga Yudhistira<sup>1)</sup>, Nutria Angraini<sup>2)</sup>,  
Ahmad Yasa<sup>1)</sup>, Irnizarifka Irnizarifka<sup>3)</sup>

<sup>1)</sup>Department of Cardiology and Vascular Medicine, Faculty of Medicine, Universitas Sebelas Maret/ Dr. Moewardi Hospital, Surakarta - Indonesia.

<sup>2)</sup>Department of Obstetric Gynecology, Faculty of Medicine, Universitas Sebelas Maret/ Dr. Moewardi Hospital, Surakarta – Indonesia.

<sup>3)</sup>Department of Cardiology and Vascular Medicine, Faculty of Medicine, Universitas Sebelas Maret/ UNS Hospital, Sukoharjo - Indonesia.

Received: 04 August 2023; Accepted: 18 August 2023; Available online: 10 October 2023

### ABSTRACT

**Background:** Patients with mechanical heart valves require lifelong oral anticoagulation. It will be a dilemma if a patient with a mechanical heart valve has surgery. This case report aims to discuss how to interrupt oral anticoagulants and bridging therapy in patients with mechanical heart valves who will be undergoing non-cardiac surgery.

**Case Report:** A 26-year-old pregnant woman, G1PoAo, a term with a mechanical mitral valve, will have elective Sectio Caesarian Transperitonealis (SCTP) surgery and Intra Uterine Device (IUD) insertion. The patient had a history of mitral valve replacement surgery (MVR) in 2014 and was routinely treated with 4 mg of warfarin at night. From the examination, blood pressure was 120/80 mmHg, heart rate was 90 beats per minute, and pulse rate was 90 beats per minute. The ECG examination found sinus rhythm with 1st-degree atrioventricular block, right axis deviation, 90 beats per minute, and left atrial enlargement. We decided to have oral anticoagulant interruption and bridging therapy by stopping warfarin three days before surgery. When the international normalized ratio (INR) falls <2, patients are given heparin injections (UFH) with an APTT target of 1.5-2.0 times from basic APTT. When the patient was about to be operated on, UFH was stopped 6 hours before surgery and resumed 12 hours after surgery. Warfarin was given one day postoperatively. Patients were adjusted to the dose of UFH according to the target. This patient had no thromboembolic events or bleeding before, during, or after surgery. The patient was allowed to be an outpatient and was given home therapy with Warfarin 5 mg at night.

**Results:** We report a case of a 26-year-old female patient with a mechanical mitral valve who was going to undergo elective SCTP surgery and an IUD insertion. Patients at high risk of thromboembolism due to surgery with a high risk of bleeding. Bridging therapy was performed using UFH. In the perioperative period, the patient did not experience thromboembolic events, and bleeding before, during, and after surgery could be well controlled.

**Conclusion:** Perioperative management of patients with mechanical heart valves must be done carefully. Interruption of oral anticoagulants should be carefully considered considering the risk of thromboembolism and bleeding during the perioperative period. Guidelines recommend that in patients with mechanical heart valves, anticoagulation interruption for minor surgeries is avoided. Whereas in patients with major surgery, it is necessary to do bridging therapy with fast-acting anticoagulants such as UFH or LMWH.

**Keywords:** mechanical heart valve, anticoagulant interruption, perioperative, bridging therapy

### Correspondence:

Trisulo Wasyanto. Department of Cardiology and Vascular Medicine, Faculty of Medicine, Sebelas Maret University / Dr. Moewardi Hospital. Jl. Kol. Sutarto 132, Surakarta 57126, Central Java, Indonesia. Email: trisulo.wasyanto@staff.uns.ac.id. ORCID ID: 0000-0001-9900-0497. Mobile: +6281-1294225.

**Cite this as:**

Wasyanto T, Yudhistira Y, Anggraini N, Yasa A, Irnizarifka I (2023). Anticoagulant Management of Mechanical Heart Valve Patients during Perioperative Surgery: A Case Report. *Indones J Med*. 08(04): 348-359. <https://doi.org/10.26911/theijmed.2023.08.04.01>.



© Trisulo Wasyanto. Published by Master's Program of Public Health, Universitas Sebelas Maret, Surakarta. This open-access article is distributed under the terms of the [Creative Commons Attribution 4.0 International \(CC BY 4.0\)](https://creativecommons.org/licenses/by/4.0/). Re-use is permitted for any purpose, provided attribution is given to the author and the source is cited.

## BACKGROUND

More than 35 million prescriptions for oral anticoagulants are written annually in the United States (Kirley et al., 2012). Some conditions that require long-term oral anticoagulant therapy include atrial fibrillation, mechanical heart valves, and arterial or venous thromboembolism (Shaikh et al., 2017; Tan et al., 2019). These patients sometimes need invasive or surgical procedures that require interruption or temporary discontinuation of oral anticoagulant therapy (Kristensen et al., 2014; Moesker et al., 2019). This condition will cause a dilemma and often cause significant side effects for patients, such as the risk of bleeding, thromboembolism, prolonged hospitalization time, increased medical costs, and increased mortality (Rechenmacher and Fang, 2015).

Patients with mechanical heart valves who will undergo non-cardiac surgery need to undergo appropriate and careful anticoagulant perioperative management so that it is not harmful to the patient (Fleiser et al., 2014; Tan et al., 2019). Assessment of the comparison of the risk of bleeding and thromboembolism necessitates bridging anticoagulant therapy during the discontinuation of warfarin in the perioperative period (Eijgenraam et al., 2014). In recent decades, discontinuing oral anticoagulants during the perioperative period has been controversial due to a lack of clinical relevance and clinical evidence (Douketis et al., 2015). The researchers conducted several trials so that a good guideline could be formed issued by the European Society of Cardiology (ESC) and

the American Heart Association (AHA) (Nishimura et al., 2014; Baumgartner et al., 2017). This case report will explain how the perioperative management of oral anticoagulants by bridging anticoagulants is in accordance with guidelines (Baumgartner et al., 2017).

## CASE PRESENTATION

Mrs. R, 26 Years old, Housewife. The patient is a consultant from the obstetrics and gynecology department of Dr. Moewardi Hospital with a diagnosis of G1POA0 term but not yet in labor, with a post-mitral valve replacement (MVR) who will be planned for elective trans peritoneal cesarean section (SCTP) surgery and insertion of an intrauterine device (IUD). Complaints of chest pain, shortness of breath, and palpitations were denied. Complaints of fever and cough were denied too. Urinate and defecate within normal limits. Complaints of swollen feet were denied. The patient is pregnant with her first child and at 37 weeks gestation.

The patient has a history of heart valve disease and has been known to suffer from severe mitral stenosis and moderate mitral regurgitation since 2012. The patient underwent mechanical mitral valve replacement surgery in 2014 at Kariadi Hospital, Semarang. The patient was then routinely monitored at the cardiac polyclinic at Dr. Moewardi hospital and treated with warfarin 4 mg/24 hours at night, candesartan 8 mg/24 hours, and bisoprolol 5 mg/24 hours. During pregnancy, the patient only took warfarin 4 mg/24 hours. After valve replace-

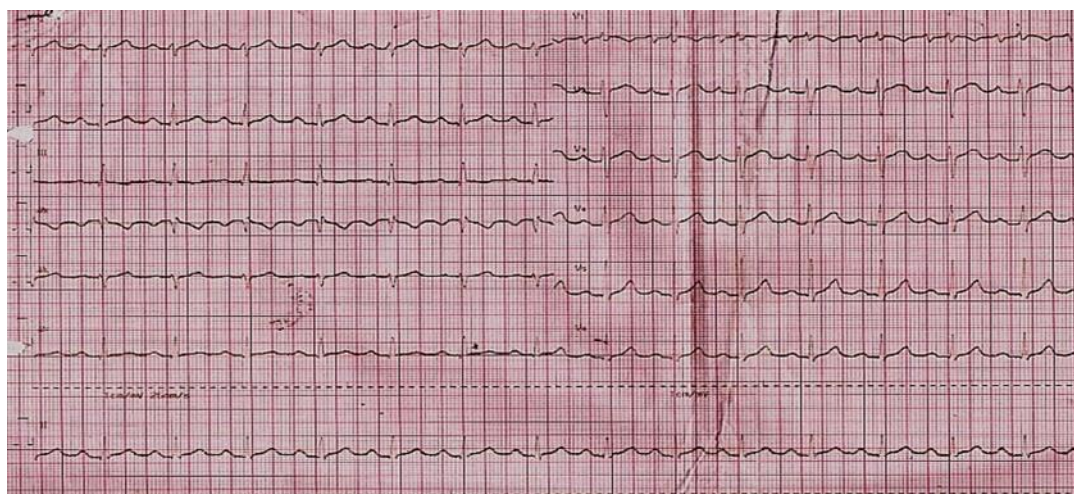
ment surgery, the patient never complained of shortness of breath, palpitations, and fatigue. History of stroke, diabetes mellitus, and high blood pressure was denied.

## RESULTS

Physical examination found that the general impression was a moderate illness with composit mentis awareness with the Glasgow Coma Scale (GCS) E4V5M6. Examination of vital signs obtained blood pressure 120/80 mmHg, heart rate 90 times per minute, pulse rate 90 times per minute, respiratory rate 18 times per minute with peripheral saturation of 99% with room oxygen, temperature obtained 36.80C. On physical examination found the eyes were not pale and the sclera was not icteric, there was no increase in jugular venous pressure, the ictus cordis was not palpable, and on percussion, the heart border was not widened; on auscul-

tation, the heart first and second sounds were normal, regular and got a metallic sound. On auscultation of the lungs, normal vesicular baseline sounds were found in both lung fields, and no additional sounds were found. On abdominal examination within normal limits. Examination of the extremities did not reveal edema and cold acral.

Electrocardiography (ECG) examination at the time of admission to the hospital obtained sinus rhythm with a heart rate of 90 beats per minute, axis deviation to the right, P duration 0.12 seconds, PR interval 0.24 seconds, QRS complex 0.04 seconds, no pathological Q waves, no ST segment elevation and ST segment depression, and no T wave inversion. From the ECG examination, it can be concluded that sinus rhythm with degree atrioventricular block 1, heart rate of 90 beats per minute, right axis deviation, and left atrial enlargement.



**Figure 1. Patient ECG'S**

Laboratory examination, found hemoglobin 10.8g/dL, hematocrit 34%, leukocytes 6,800-/ul, platelets 247,000/ul, erythrocytes 3.80 million/ul, random blood sugar 85 mg/dl, creatinine 0.5 mg/dl, urea 9 mg/dl, serum glutamic oxaloacetic transaminase (SGOT) 11 u/l, serum glutamic pyruvate transaminase (SGPT) 7 u/l, prothrombin time (PT)

31.2 seconds, activated partial thromboplastin time (APTT) 39.5 seconds, international normalized ratio (INR) 3.15, sodium 132 mmol/l, potassium 3.5 mmol/l, chloride 110 mmol/l.

From echocardiographic examination (figure 3) found normal left ventricular mass, good left ventricular contractility with

ejection fraction of 66%, grade 1 diastolic dysfunction, good right ventricular contractility with tricuspid annular plane systolic excursion (TAPSE) 2.0 cm, normal left ventricular and right ventricular dimensions, left atrial dimension dilated, normal kinetic global wall movement, obtained mechanical prosthetic valve with acoustic shadow with good valve position and function with Effective Orifice Area (EO) 2.3 cm and Diastolic Velocity Integral (DVI) 0.29, no leaks, no thrombus and no vegetation found on the

prosthetic valve, mild tricuspid regurgitation and mild aortic regurgitation and Left Atrial Volume Index (LAVI) 31.76 ml/m<sup>2</sup>. From the echocardiography, it was concluded that the post-mitral valve replacement (MVR) mechanical prosthetic valve was in good position and function, with no leaks, no thrombus and no vegetation, good left ventricular contractility, grade 1 diastolic dysfunction, moderate tricuspid regurgitation, and mild aortic regurgitation.

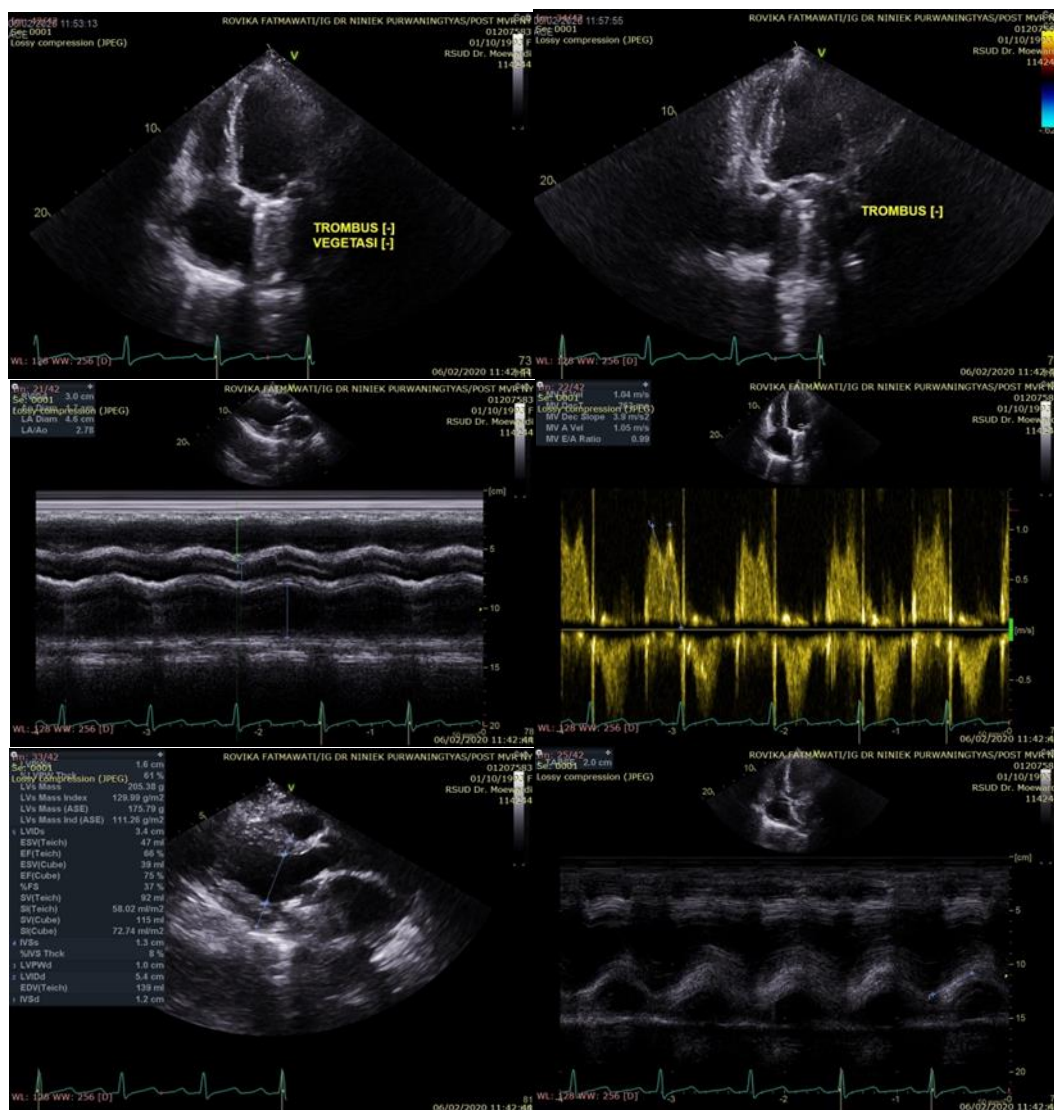


Figure 3. Patient echocardiography's

The patient was diagnosed with a mechanical heart valve after MVR in 2014 et causa

severe mitral stenosis and moderate mitral regurgitation with the New York Heart Asso-

ciation (NYHA) functional class grade I, with accompanying G1PoAo 37 weeks gestation, not yet in labor pro elective SCTP surgery and IUD insertion. The patient was given a treatment plan to stop warfarin three days before surgery, INR check per day, and if INR < 2, give heparin bolus injections of 60 units/kg followed by 12 units/kg/hour, APTT check per day with an APTT target of 50-70 seconds, agree to surgery if the target INR is < 2 with a moderate risk of action, stop Unfractionated Heparin (UFH) injection 6 hours before surgery.

At the time of admission to the hospital, a laboratory examination was carried out, and the result was INR 1.58. The patient weighs 70 kg, so he is given a bolus UFH injection of 60 units/kg (4200 units) followed by 12 units/kg/hour (8400 units/hour) and plans to monitor APTT/day with an APTT target of 1.5-2.0 times from the basic APTT value or APTT target between 40.1-53.4 seconds. The patient was re-laboratory examined the next day; the APTT result was 38.5 seconds, and the patient was given a UFH injection with the dose increased by two units to 14 units/kg/hour (980 units/hour). From the obstetrics and gynecology department, the patient is planned for SCTP surgery. The patient was given UFH injection therapy of 14 units/kg/hour (980 units/hour); the UFH injection stopped 6 hours before surgery.

The patient was operated on two days later. The patient experienced bleeding during surgery of around  $\pm 500$  ml, and the surgical wound looked good. At that time, the patient was diagnosed with post-MVR mechanical heart valves in 2014, NYHA I with elective post-SCTP in term pregnant primigravidas. The patient underwent laboratory examination and obtained an APTT of 30.4 seconds and an INR of 1.04. The patient is planned to start administering UFH injection of 14 units/kg/hour (980

units/hour) 12 hours postoperatively and warfarin 2 mg/24 hours the next day. From the results of laboratory tests the next day, the APTT was 29.5 seconds and INR 0.96. The patient currently weighs 60 kg, so he was given a repeat UFH bolus injection of 60 units/kg (3600 units) followed by an increased dose of 14 units/kg/hour (840 units/hour), starting with warfarin 2 mg/24 hours at night and planning to check the APTT and INR tomorrow morning. The next day the APTT laboratory results were 41.0 seconds and INR 0.99, the patient was given a UFH injection, followed by a dose of 14 units/kg/hour (840 units/hour), and the warfarin dose was increased to 4 mg at night. The next day, the APTT target was achieved in 34.7 seconds and INR 1.05. The patient was given UFH injection with the dose increased to 16 units/kg/hour (960 units/hour) and the same dose of warfarin to 4 mg/24 hours at night. The next day, the patient was planning to go home from the obstetrics and gynecology department, and the APTT was 40.7 seconds and INR 1.84. The patient was then sent home with warfarin therapy, increased by 5 mg/24 hours at night, and planned to re-check the INR during control at the cardiac polyclinic. The patient went to the cardiac polyclinic for control seven days later and obtained an INR of 2.52. The patient received outpatient therapy which is warfarin 5 mg/24 hours at night.

## DISCUSSION

### Definition of Bridging Anticoagulant

Bridging anticoagulant is administering blood thinners with a short duration of action for 10-12 days in a period of action or surgery (Douketis et al., 2012). Bridging therapy using UFH or Low Molecular Weight Heparin (LMWH) has been empirically proven to reduce the risk of thromboembolism during the anticoagulant interruption period

and reduce the risk of bleeding complications after surgery (Nishimura et al., 2017). Anticoagulant bridging therapy is usually carried out when warfarin is stopped, and the anticoagulant effect is lost because it is outside the target of therapy (Douketis et al., 2012).

### **Long-Term Oral Anticoagulants Indications**

Long-term oral anticoagulants are used to prevent thromboembolism. Patients with cases of atrial fibrillation, mechanical heart valves, and VTE have a high risk of thromboembolism (Tafur and Douketis, 2018). In patients with mechanical heart valves, the recommended oral anticoagulant is warfarin. Meanwhile, novel anticoagulants (NOAC) have not been recommended for use in patients with mechanical heart valves (Nishimura et al., 2014; Baumgartner et al., 2017).

Prior to treatment, the clinician must assess whether interruption of anticoagulation will result in a thromboembolic event on a case-by-case basis. Various cases and conditions will be classified to assess the possibility of thromboembolic events during invasive or surgical procedures (Rechenmacher and Fang, 2015). Low risk procedure (risk per year <5%) include bileaflet aortic valve without other risk factors, CHADS<sub>2</sub> Score of 0-2 without history of stroke/TIA and VTE >12 months without other risk factors. Moderate risk procedure (risk per year 5-10%) include bileaflet aortic valve and other risk factors, CHADS<sub>2</sub> Score of 3-4, VTE within 3-12 months, thrombophilia other than severe, recurrent VTE and active cancer. High risk procedure (risk per year >10%) include mitral prosthetic valve, cage ball or tilting disc aortic valve prosthetics, stroke/TIA within 6 months, CHADS<sub>2</sub> score of 5-6, stroke/TIA within 3 months, rheumatic valvular heart disease, VTE <3 months and severe thrombophilia. (Douketis et al.,

2012) In this case, patients with mechanical mitral prosthetic valves are included in the high-risk category of thromboembolism.

Patients with mechanical heart valves using long-term warfarin need to have INR monitored periodically. The target INR for mechanical heart valves varies depending on the type of valve used and factors increasing the incidence of thrombosis. The types of valves used today are mostly less thrombogenic than earlier types of valves. For this type of valve, there is data on anticoagulants and systemic embolism based on various previous prospective or retrospective studies (Keeling et al., 2011).

Various INR targets for various mechanical heart valves have been explained. In low prosthesis thrombogenicity types such as Carbomedics, Medtronic Hall, St. Jude Medical, and ON-X have a target for 2.5–3.0 depending on whether it has no risk factor or has  $\geq 1$  risk factors. Medium prosthesis thrombogenicity types such as other bileaflet valves have targets of 3.0 – 3.5 and high prosthesis thrombogenicity types (Lillehei-Kaster, Omniscience, Starr-Edwards, Bjork-Shiley and other tilting-disc valves) have target about 3.5–4.0. In this case, based on the guidelines, the target INR used was 2.5-3.0 because she was a mechanical heart valve patient in the mitral using the ST Jude Medical type of leaflet valve accompanied by an additional risk factor that is mitral valve replacement (Baumgartner et al., 2017).

### **Thromboembolism vs. Bleeding**

Clinicians think that interruption of oral anticoagulant administration can cause thromboembolism, which increases the risk of death by 20% and increases the risk of major disability by 40% (Tan et al., 2019). Thromboembolism is defined as valvular thrombus, stroke, transient ischemic attack (TIA), unstable angina, myocardial infarction, or systemic embolism (Bitekter et al., 2012). The estimated annual risk of thromboembo-

lism in mechanical heart valves is 8% to 22% (Tan et al., 2019). Using warfarin, the risk of thromboembolism drops by 80% (Whitlock et al., 2012). Overall, perioperative thromboembolic events are rare. In general, in patients who were not undergo bridging anticoagulants, the estimated thromboembolism was around 0.53% based on various reviews of 70 studies from 1966 to 2015 (Rechenmacher and Fang, 2015). Whereas for patients with mechanical heart valves, it is stated that the risk of perioperative thromboembolism is around 1% (Wysokinski and McBane, 2012)

Bridging therapy will increase the risk of major bleeding perioperatively by around 4%-8% and is related to the INR value (Tan et al., 2019). From various observational data, bleeding events during surgery are more common than thromboembolic events during the perioperative period. Recent data states that the ratio of bleeding to thrombosis ranges from 13:1 in patients undergoing bridging therapy and 5:1 without bridging therapy (Rechenmacher and Fang, 2015). A systematic review and meta-analysis of 34 observational studies found a higher risk of major bleeding events with an odds ratio of 3.6 (95% confidence interval: 1.52-8.50) in patients undergoing bridging therapy compared to no bridging therapy and no events of significant thromboembolism between the two groups (Siegal et al., 2012). Because systemic embolic events are more dangerous than bleeding, an increase in the bleeding-thrombosis ratio is still acceptable (Rechenmacher and Fang, 2015).

The incidence of bleeding is one marker of poor outcomes. For example, anticoagulant-related bleeding is associated with increased morbidity and mortality, which has been widely published in many medical, interventional, and surgical cases (Siegal et al., 2012). Some data shows that the incidence of bleeding will also increase the

length of stay in the hospital and increase the cost of treatment. From the review above, we can conclude that thromboembolic events in the perioperative period are rare, and bleeding events occur more than thromboembolism in patients who are given bridging (Rechenmacher and Fang, 2015).

#### **Warfarin Use During Pregnancy**

Pregnant women with mechanical heart valves have a high rate of complications. The ROPAC registry states that the probability of being free of complications during pregnancy in women with mechanical heart valves is 58% (van Hagen et al., 2015). Complications during pregnancy in women with mechanical heart valves are mainly due to the use of warfarin oral anticoagulants, which can cause valve thrombosis and the risk of bleeding (Hassouna and Allam, 2014). The risk of valvular thrombosis increases during pregnancy, but with adequate anticoagulant administration, the risk is reduced (Regitz-Zagrosek et al., 2018). Giving low-dose warfarin has a small risk of valve thrombosis, which is 0-4% (Xu et al., 2016).

Based on the 2018 ESC guidelines, it is stated that the use of warfarin during pregnancy in women with mechanical heart valves is the safest anticoagulant choice compared to other anticoagulants such as LMWH or UFH (Regitz-Zagrosek et al., 2018). The use of warfarin in mechanical heart valves has the lowest risk of valve thrombosis (Chan et al., 2000).

As is well known, warfarin is teratogenic. Warfarin can cross the placental barrier, whereas LMWH and UFH cannot cross the placental barrier. Two systematic review studies stated that the risk of miscarriage is highly dependent on the dose of warfarin (Hassouna and Allam, 2014; Xu et al., 2016). The incidence of embryopathy (limb deformities, nasal hypoplasia) in the use of warfarin in the first trimester is 0.6-10% of cases. Whereas with low-dose war-

farin, it is around 0.45-0.9% of cases (Xu et al., 2016). Whereas in general, the use of warfarin carries a low risk of embryopathy, fetopathy (<2%), and fetal loss (<20%). So warfarin is the most effective choice of regimen for preventing thrombosis (Chan et al., 2000; Regitz-Zagrosek et al., 2018).

In this patient, low-dose warfarin, <5 mg, was continued from the first trimester because it has the least embryopathy risk and the lowest thrombosis risk compared to other anticoagulants with recommendation class 2A. Meanwhile, the use of low-dose warfarin is recommended in the second and third trimesters with a 1C class recommendation. SCTP surgery is performed in patients because it is the safest delivery procedure for both mother and fetus (Regitz-Zagrosek et al., 2018).

#### **Preoperative Assessment: Need to Interrupt Oral Anticoagulation?**

Oral anticoagulation during invasive or surgical procedures requires careful management based on an assessment of the risk of thromboembolism and bleeding (Baumgartner et al., 2017). As a clinician, the decision to use anticoagulants is assessed individually by considering the risk of thromboembolism and bleeding by looking at the type of action or surgery, risk factors, and the type, location, and number of prosthetic heart valves (Nishimura et al., 2014).

Before deciding to discontinue oral anticoagulants, as clinicians, we must assess whether the surgical procedure has a high risk of bleeding (Tan et al., 2019). In principle, we should avoid stopping oral anticoagulants as much as possible, especially for minor procedures or actions (Rechenmacher and Fang, 2015). In the 2014 AHA guidelines, it is stated that continuing warfarin anticoagulant administration with an INR according to the target is recommended for patients with mechanical heart valves who will undergo minor procedures (such as

tooth extraction or cataract surgery) when the risk of bleeding is easily controlled with recommendations for class 1 and level of evidence (LOE) C (Nishimura et al., 2014). Several procedures may not require stopping warfarin, including endoscopy, biopsy, endovascular intervention, percutaneous coronary intervention, cardiac electrophysiology studies and cardiac ablation, implantation of cardiac devices, cataract surgery, dermatological surgery, tooth extraction, epidural anesthesia, pain management intervention, minor non-cardiac operation, total knee arthroplasty surgery, and arthroscopic surgery (Rechenmacher and Fang, 2015).

In this case, the patient will undergo elective SCTP surgery, and we assess that the operation includes a high bleeding risk requiring discontinuation of oral anticoagulants, namely warfarin, and bridging therapy using UFH.

If interruption of oral anticoagulation is necessary, as much as possible, avoid bridging therapy, especially in patients with low or moderate thromboembolic risk, and assessment between individuals (Rechenmacher and Fang, 2015). Patients who have a specific bleeding risk need guidance on assessing anticoagulant use. Bleeding itself does not only depend on the type of procedure but there are other specific clinical risk factors (Tan et al., 2019). One method that can be used is the BleedMAP score (Rechenmacher and Fang, 2015). The BleedMAP score is based on a retrospective study of 2484 patients with perioperative interruption of oral anticoagulants at the Mayo Clinic Thrombophilia Center from 1997 to 2007. The BleedMAP score will help clinicians to assess the risk of bleeding based on four basic clinical variables that are a history of prior bleeding (bleed), mechanical mitral valve (M), active cancer (A), and thrombocytopenia <15000/ul or low platelets (P) (Tafur et al., 2012). A higher BleedMAP score



indicates a higher risk of bleeding and is associated with a lower risk of thromboembolic events (Rechenmacher and Fang, 2015). Meanwhile, the 2014 AHA guidelines state that anticoagulant bridging with both intravenous UFH and LMWH is recommended during the time interval when the INR value is below the therapeutic value in patients undergoing invasive or surgical procedures with 1). Aortic mechanical valve with risk factors for thromboembolism, 2). Old generation aortic mechanical valve, 3). Mechanical mitral valve with class 1 recommendations and LOE C.

Among patients with chronic oral anticoagulant (OAC) users in the perioperative phase, several conditions where anticoagulant bridging and OAC interruption are indicated include high thromboembolic risk when the risk of thromboembolic clearly outweighs the increased risk of bleeding from bridging, in intermediate risk of thromboembolic with the indication of OAC is not caused by atrial fibrillation and the thromboembolic risk clearly outweigh the increased risk of bleeding from bridging. Others may interrupt their OAC without the need for anticoagulant bridging, including intermediate thromboembolic risk with AF for the indication of OAC and low thromboembolic risk. Patients with low bleeding risk may continue their OAC with the surgeon willing, and patients who no longer require oral anticoagulants may consider discontinuing their OAC (Rechenmacher and Fang, 2015).

So, from several guidelines, we can conclude several essential things. Firstly, oral anticoagulants should not be discontinued for procedures with low bleeding risk. Second, patients with a high risk of thromboembolism and without the risk of major bleeding during the procedure should be considered for bridging anticoagulants. Conversely, bridging should not be done if the

thromboembolic risk is low. Third, in cases with a moderate risk of thromboembolism, clinicians should assess and consider case by case the risk of thromboembolism and bleeding (Rechenmacher and Fang, 2015).

### **Bridging Therapy Strategies in Mechanical Heart Valves**

In patients with high thromboembolic risk, such as patients with a mechanical mitral valve, who will be undergoing major surgical procedures, bridging therapy is needed (Nishimura et al., 2014). In patients with mechanical heart valves, oral anticoagulation should be discontinued before surgery, and heparin bridging is recommended. UFH is a heparin therapy approved for bridging therapy in mechanical heart valves. The choice of UFH takes precedence over the use of LMWH. LMWH subcutaneously itself was chosen as an alternative to UFH. Meanwhile, the use of fondaparinux is not recommended for bridging therapy in patients with mechanical heart valves (Baumgartner et al., 2017).

The 2017 ESC guidelines for stopping oral anticoagulants carried out five days before surgery so that the effect of warfarin can decrease gradually, while the 2014 AHA guidelines, it is stated that oral anticoagulant therapy can be stopped 2-4 days before surgery (Baumgartner et al., 2017; Nishimura et al., 2014). Broadly speaking, for major operations with moderate-to-large bleeding risk, a target INR <1.5 is needed to reduce the risk of bleeding (Baumgartner et al., 2017). Bridging anticoagulant therapy using either intravenous UFH or subcutaneous LMWH is started when INR <2 (usually around 48 hours before surgery) and stopped 4-6 hours before surgery if using UFH, whereas if using LMWH, it is stopped 12 hours before surgery. If LMWH is used for bridging therapy, give the dose adjusted according to body weight and given twice a day. UFH and LMWH will be resumed 12-24 hours after surgery, and warfarin will be

resumed the first day after surgery (Baumgartner et al., 2017).

In this case, warfarin was discontinued three days before surgery, and daily INR was checked to see a gradual decrease in INR. On the second day before surgery, INR <2, and we started bridging therapy using UFH with a target APTT of 1.5-2.0 times the baseline APTT. Then we adjusted the heparin dose according to the target until the D-day of surgery. The operation was planned to be carried out at 09.00, so we stopped UFH 6 hours before the operation, which was at 03.00. The patient finished the operation and returned to the ward at 11.00. We resumed UFH 6 hours after surgery at 17.00 on the same day using the last dose of UFH before it was discontinued. On day 1, after surgery, we started warfarin therapy at an initial dose of 2 mg. Then the patient is monitored for INR and APTT values according to the target while providing dose adjustments and assessing the risk of thromboembolism and postoperative bleeding. On the day fourth after surgery, the patient was sent home with warfarin therapy using a dose adjustment based on the INR value.

One case was reported as a 26-year-old female patient G1POAO a term with a mechanical mitral valve who was going to undergo elective SCTP surgery and insert an IUD. Patients are at high risk for thromboembolic events and will undergo surgery with a high risk of bleeding. Considering the risk of thromboembolism and bleeding, oral anticoagulant therapy, that is, warfarin, was interrupted, and bridging therapy was carried out using UFH during the perioperative period. In the perioperative period, the patient did not experience thromboembolic events, and bleeding during and after surgery was well controlled.

Based on ESC and AHA guidelines, oral anticoagulants in patients with mechanical heart valves should not be stopped

during minor procedures or actions. However, bridging therapy is recommended for patients undergoing procedures or operations with a moderate-high risk of bleeding. The preferred bridging therapy is UFH, which is started when warfarin is discontinued 2-4 days before surgery. UFH was stopped 6 hours before surgery and resumed 12-24 hours after surgery, accompanied by continued warfarin therapy. Bridging therapy aims to reduce the risk of thromboembolism and reduce the risk of bleeding during the perioperative period.

#### **AUTHOR CONTRIBUTION**

Trisulo Wasyanto is the main author who determines the concept and review. Ahmad Yasa, Irnizarifka, Yoga Yudhistira and Nutria Anggraini searching for literature, editing and reviews.

#### **FINANCIAL AND SPONSORSHIP**

None.

#### **ACKNOWLEDGEMENT**

We would like to thank to Dr. Moewardi Hospital that give permission to collect the data.

#### **CONFLICT OF INTEREST**

The authors declare there is no conflict of interest.

#### **REFERENCE**

- Baumgartner H, Falk V, Lancellotti P, Lansac E, Rosenhek R, Sjögren J, Vahanian A, et al. (2017). ESC/EACTS Guidelines for the management of valvular heart disease. *Eur Heart J.* 38: 2739-91.
- Biteker M, Tekkesin AI, Can MM, Dayan A, Ilhan E, Türkmen FM (2012). Outcome of non-cardiac and nonvascular surgery in patients with mechanical heart valves. *Am J Cardiol.* 110: 562-7.

- Chan WS, Anand S, and Ginsberg JS (2000). Anticoagulation of pregnant women with mechanical heart valves: A systematic review of the literature. *Arch Intern Med.* 160: 191-6.
- Daniels PR, McBane RD, Litin SC, Ward SA, Hodge DO, Dowling NF, Heit JA, et al. (2009). Perioperative anticoagulation management of mechanical heart valve patients. *Thromb Res*; 124: 300-5.
- Douketis JD, Spyropoulos AC, Kaatz S, et al. (2012). Bridging anticoagulation: Is it needed when warfarin is interrupted around the time of a surgery or procedure? *Circulation.* 125: e496-8.
- Douketis JD, Spyropoulos AC, Spencer FA, Michael M, Jaffer AK, Eckman MH, Dunn AS, et al. (2012). Perioperative management of antithrombotic therapy: antithrombotic therapy and prevention of thrombosis, 9th ed: American College of Chest Physicians evidence-based clinical practice guidelines. *Chest.* 141: e326S-50S.
- Douketis JD, Spyropoulos AC, Kaatz S, Becker RC. 2015. Perioperative bridging anticoagulation in patients with atrial fibrillation. *N Eng J Med.* 373(9): 823-33.
- Eijgenraam P, ten Cate H, and ten Cate-Hoek AJ. 2014. The practice of bridging anticoagulation: guideline adherence and risk factors for bleeding. *Neth J Med.* 72(3): 157-64.
- Fleiser LA, Fleischmann KE, Aurbach AD, Bernason SA, Beckman JA, Bozkurt B, Davila-Roman VG, et al. 2014. ACC/AHA Guideline on perioperative cardiovascular evaluation and management of patients undergoing non-cardiac surgery. *J Am Coll Cardiol.* 64(22): e77-137.
- Hassouna A and Allam H. 2014. Limited dose warfarin throughout pregnancy in patients with mechanical heart valve prosthesis: A meta-analysis. *Interact Cardiovasc Thorac Surg.* 18: 797-806.
- Keeling D, Baglin T, Taite C, Watson H, Perry D, Baglin C, Kitchen S, et al. (2011). Guidelines on oral anticoagulation with warfarin-fourth edition. *Br J Haematol.* 154(3): 311-24.
- Kirley K, Qato DM, Kornfield R, Stafford RS, Alexander GC. (2012). National trends in oral anticoagulant use in the United States, 2007 to 2012. *Circ Cardiovasc Qual.* 5: 615-21.
- Kristensen SD, Knuuti J, Saraste A, Anker S, Hert SD, Ford I, Gonzalez-Juanatey R, et al. (2014). ESC/ESA Guidelines on non-cardiac surgery: cardiovascular assessment and management. *Eur Heart J.* 35: 2383-431.
- Moesker MJ, de Groot JF, Damen NL, Bijsterveld NR, Twisk JWR, Huisman MV, Wagner C, et al. (2019). Guideline compliance for bridging anticoagulation use in vitamin-K antagonist patients; practice variation and factors associated with non-compliance. *Throm J.* 17:15.
- Nishimura RA, Otto CM, Bonow RO, Carabello BA, Erwinlll JP, Guyton RA, O’Gara PT, et al. (2014). AHA/ACC Guideline for the management of patients with valvular heart disease. *J Am Coll Cardiol.* 63(22): e57-185.
- Nishimura RA, Otto CM, Bonow RO, Carabello BA, Erwinlll JP, Guyton RA, O’Gara PT, et al. (2017). 2017 AHA/ACC Focused Update of the 2014 AHA/ACC Guideline for the management of patients with valvular heart disease. *J Am Coll Cardiol.* 70(2): 252-89.
- Rechenmacher SJ and Fang JC. 2015. Bridging anticoagulation. *J Am Coll Cardiol.* 66(12): 392-403.
- Regitz-Zagrosek V, Roos-Hesselink JW, Bausersachs J, Bonis MD, Lung B, John-

- son MR, Kintscher U, Kranke P, et al. (2018). ESC Guideline for the management of cardiovascular diseases during pregnancy. *Eur Heart J*. 00: 1-83.
- Shaikh SI, Kumari RV, Hegade G, Maruthesh M. 2017. Perioperative considerations and management of patients receiving anticoagulants. *Anesth Essays Res*. 11(1): 10-16.
- Siegal D, Yudin J, Kaatz S, Douketis JD, Lim W, Spyropoulos AC. (2012). Periprocedural heparin bridging in patients receiving vitamin K antagonists: a systematic review and meta-analysis of bleeding and thromboembolic rates. *Circulation*. 126: 1630-9.
- Tafur AJ, McBane R, Wysokinski WE, Litin S, Daniels P, Slusser J, Hodge D, Beckman G, et al. (2012). Predictors major bleeding in periprocedural anticoagulation management. *J Thromb Haemost*. 10(2): 261-7.
- Tafur AJ and Douketis J (2018). Perioperative management of anticoagulant and antiplatelet therapy. *Heart*. 104. 1-461-7.
- Tan CW, Wall M, Rosengart TK, Rosengart TK, Ghanta RK (2019). How to bridge? Management of anticoagulation in patients with mechanical heart valves undergoing non-cardiac surgical procedures. *J Thorac Cardiovascular Surg*. 158(1): 200-3.
- Van Hagen IM, Roos-Hesselink JW, Ruys TP, Merz WM, Goland S, Gabriel H, Lelonek M, et al. (2015). Pregnancy in women with a mechanical heart valve: Data of the European Society of Cardiology Registry of Pregnancy and Cardiac Disease (ROPAC). *Circulation*. 132: 132-42.
- Whitlock RP, Sun JC, Frenes SE, Rubens FD, Teoh KH. 2012. Antithrombotic and thrombolytic therapy for valvular heart disease: antithrombotic therapy and prevention of thrombosis, 9th Ed: American College of Chest Physicians evidence-based clinical practice guidelines. *Chest*. 141(2): e576S-600S.
- Wysokinski WE and McBane RD II (2012). Periprocedural bridging management of anticoagulation. *Circulation*. 126: 4-86-90.
- Xu Z, Fan J, Luo X, Zhang W, Ma J, Lin Y, Ma S, et al. (2016). Anticoagulation regimens during pregnancy in patients with mechanical heart valves: A systematic review and meta-analysis. *Can J Cardiol*. 32: 1248.e1-1248.e9